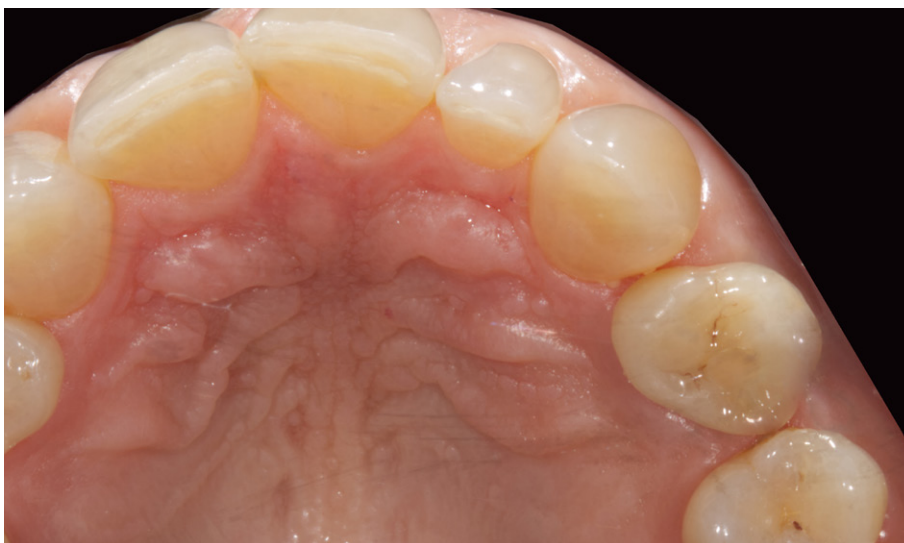
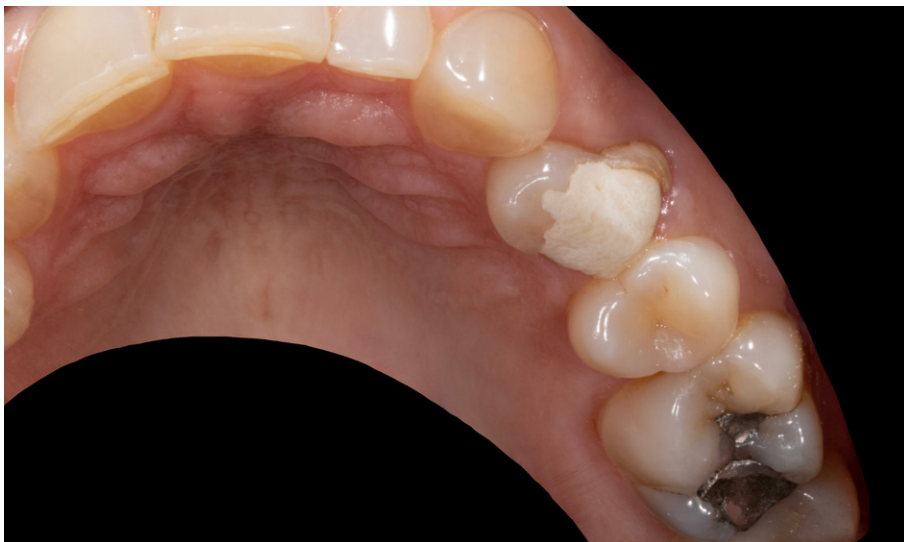

Digital workflow in Implantology. Planning of implant prosthetics, extraction, implantation and provisionalisation for a fractured tooth



Dr. Thibaud Casas
Dentist

CASE REPORT

Digital workflow in Implantology. Planning of implant prosthetics, extraction, implantation and provisionalisation for a fractured tooth

» In the event of an accident or an unforeseen incident; patients desire an immediate return of oral function and esthetics. An immediate implant coupled with an immediate restoration are techniques that can fulfil patients' expectations, but require a detailed evaluation of the patient's medical history as well as an in-depth analysis of the soft tissue, the bone, and the biotype [Linkevicius et al. 2015]. The patient must also be informed about the different treatment options available and the corresponding procedures [Simensen et al 2015, Yao et al. 2017]. One of the advantages of immediate implantation with immediate restoration using a digital workflow, is the significant reduction in treatment duration. [Zhang et al. 2019]

Clinical Case

The 45-year-old patient presents a longitudinal fracture of the dental root of tooth 24, which features an extensive composite restoration. (1a-b).

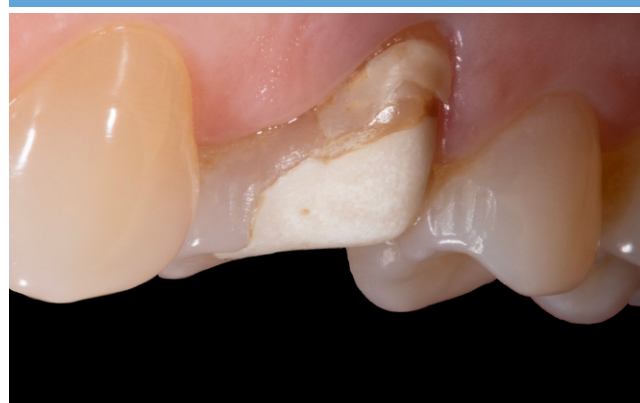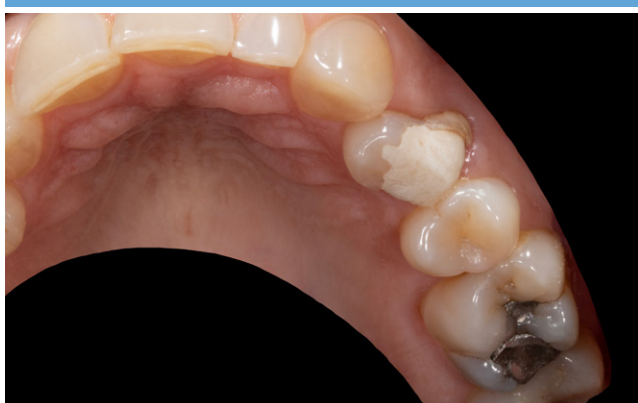The patient also has excellent dental hygiene with a favourable gingival biotype and no signs of inflammation. A cone beam CT (CBCT) was carried out; the clinical and X-ray findings support an immediate extraction/implantation procedure followed by an immediate provisionalisation. This was in keeping with the patient's request. An optical impression was carried out using a 3Shape TRIOS 3 intraoral scanner (Copenhagen, Denmark) (2a-b). This acquired impression was combined with the data extracted from the DICOM file and from the CBCT for the implant procedural planning (3Shape ImplantStudio) (3a-c). A surgical guide was produced in Clear LT biocompatible resin (Formlabs Form2, Somerville, US) (4a-c); simultaneously the temporary prosthesis was manufactured in PMMA and assembled with the help of the Panavia V5 Opaque (Kuraray, Noritake, Japan) on a titanium base (5a-b, 6).

The tooth was extracted with a non-invasive, atraumatic method using the piezotome (MECTRON Piezo Touch, Carosco, Italy) while keeping the vestibular wall intact (class II bone), making it possible to fit a CAMLOG® PROGRESSIVE-LINE implant, L 13 mm and Ø 4.3 mm (7a-b).

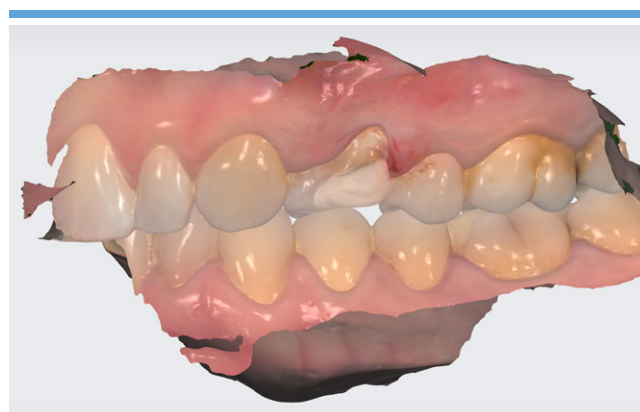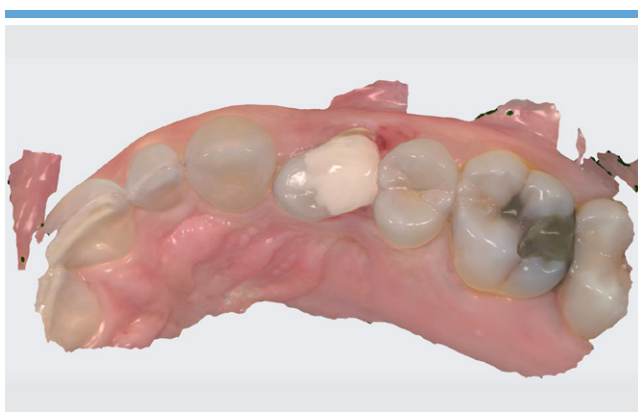The implant was inserted using an insertion torque of 47 Ncm and demonstrates excellent primary stability, allowing the provisional prosthesis to be fitted as planned. The vestibular cavity between the implant and the alveolus is filled using a bone substitute material (Bio-Oss®, Geistlich Pharma AG, Wolhusen, Switzerland). A light diet is prescribed for a period of two weeks. The patient is advised to use a soft toothbrush and rinse their mouth with a preparation

of chlorhexidine 0.1% for the same period (8-12).

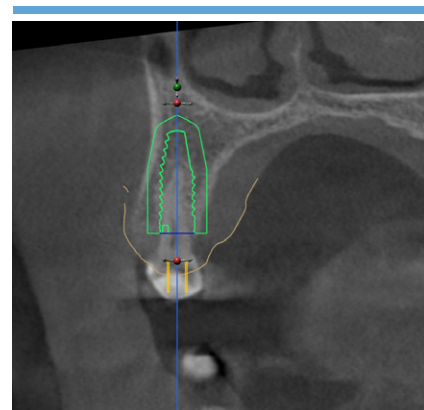
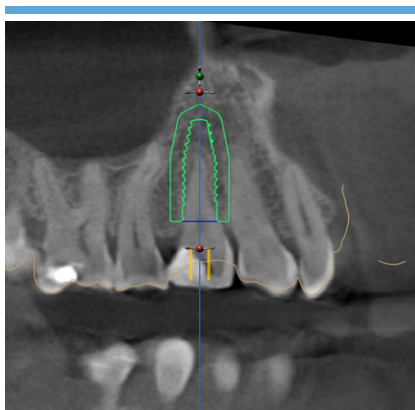
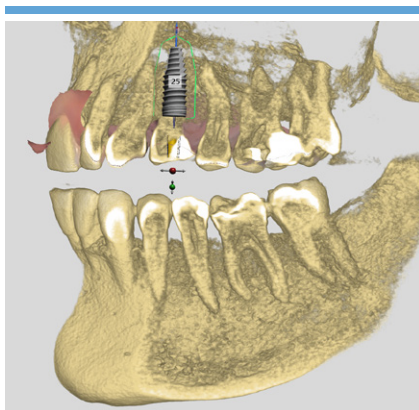
Ten days post-surgery, the patient comes back for the removal of the sutures and a check-up (13). The tissue around the implant is a healthy colour with no signs of any complications. The fitting of the permanent prosthesis is scheduled for three months post-implantation (14a-b).



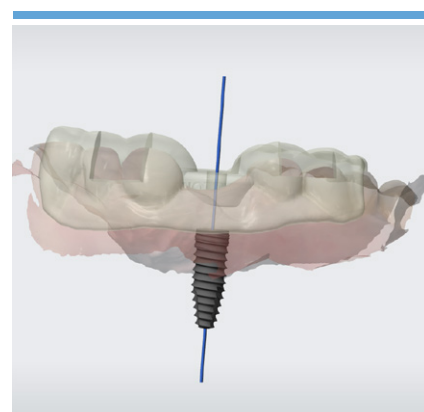
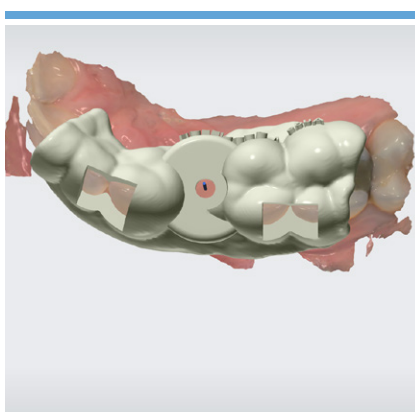
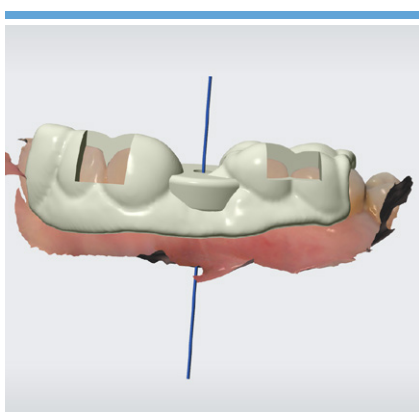
1a and 1b. Initial occlusal (1a) and lateral (1b) views.



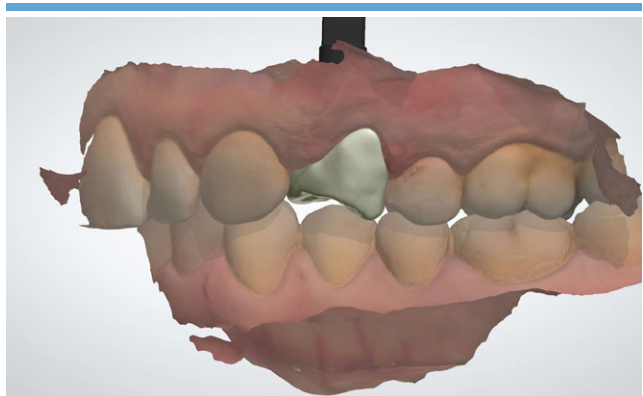
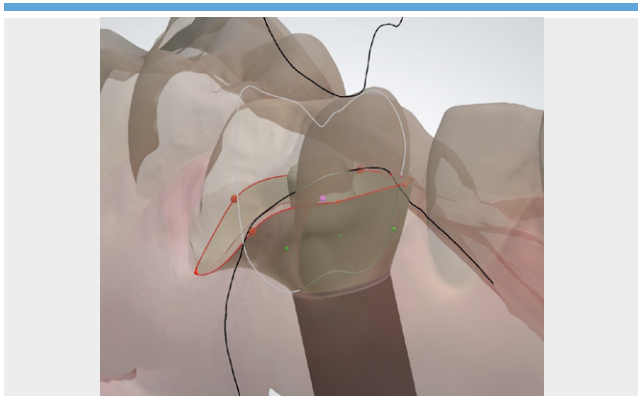
2a and 2b. An optical impression (3Shape TRIOS 3) was carried out at the pre-visit.



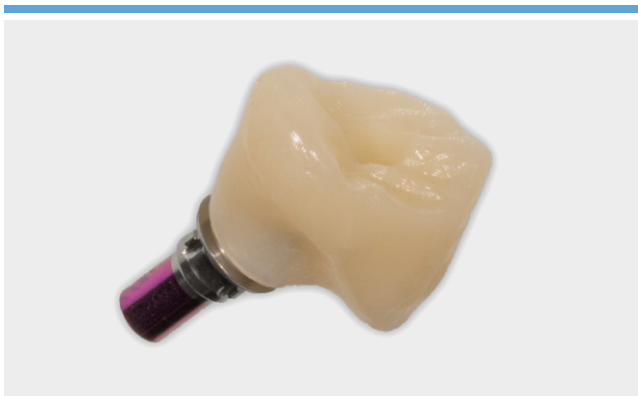3a, 3b and 3c. The optical impression was combined with the CBCT images for the planning of the implant (3Shape Implant Studio).



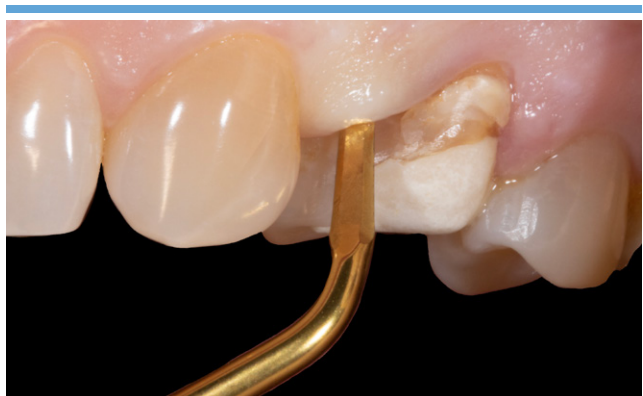4a, 4b and 4c. Creation of the surgical guide (3Shape Implant Studio).



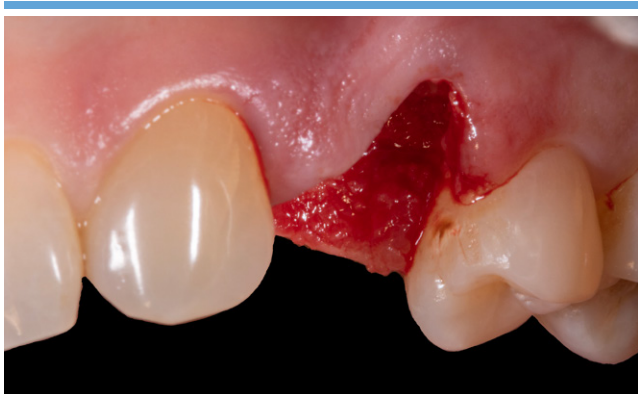5a and 5b. The provisional prosthesis was designed at the same time as the guide, ahead of the surgery. The emergence profile was adapted to the anatomy.



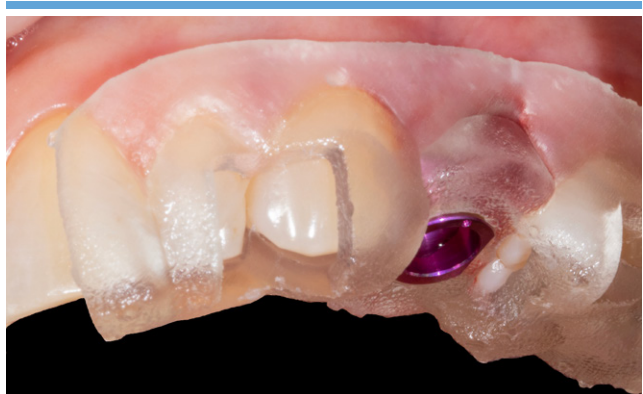6. Then machined in PMMA and assembled on a titanium base.



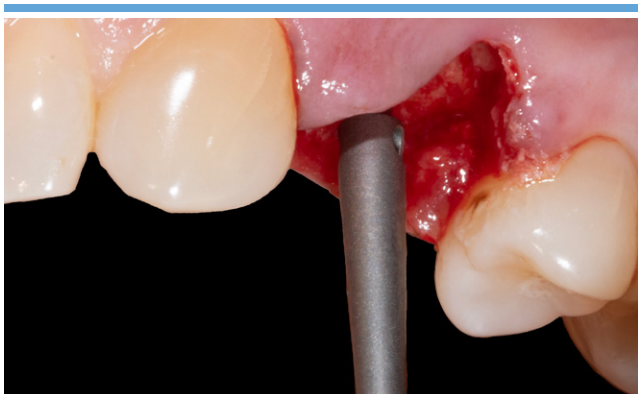7. Atraumatic avulsion using the piezotome.



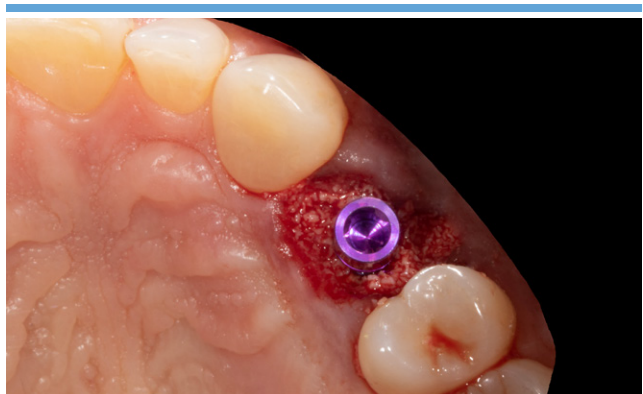7b. Post-extraction site.



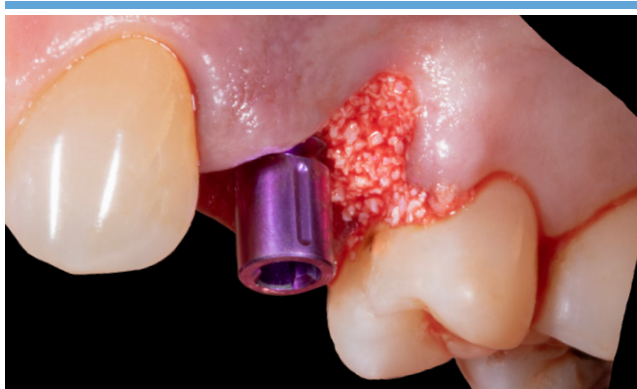8. Surgical guide in position.



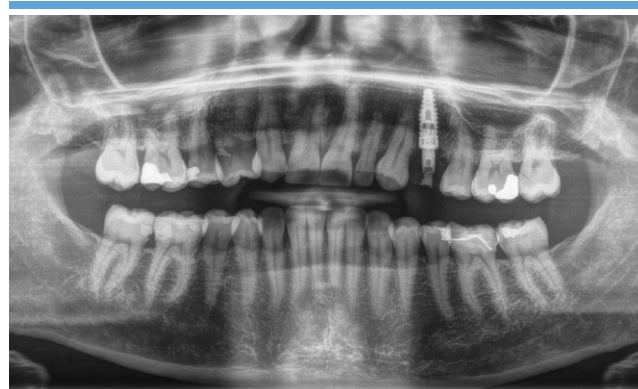9. Depth gauge to check the implant axis.



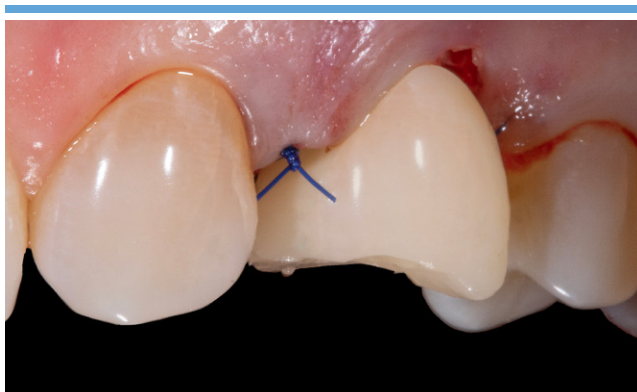
10a. Fitting of CAMLOG PROGRESSIVE-LINE implant and augmentation (Bio-Oss).



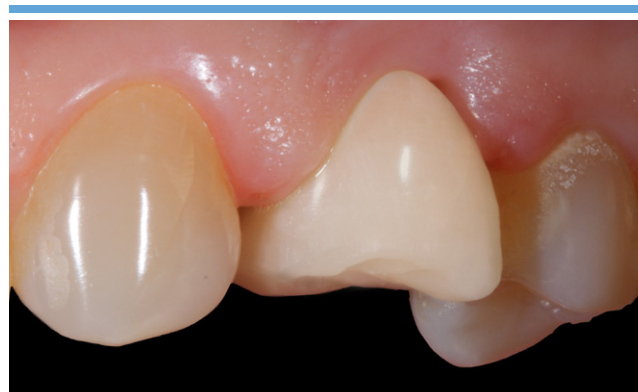10b. Lateral view of the implant in place and augmented situs.



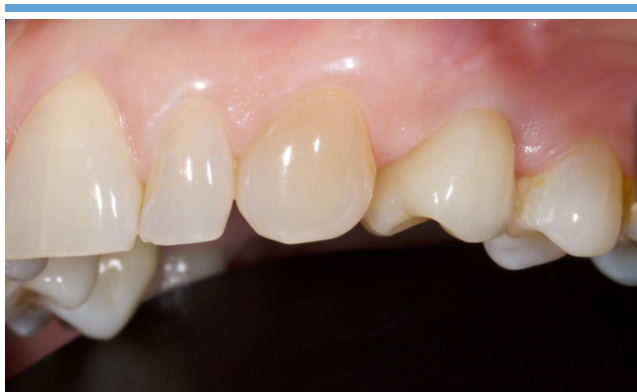11. Post-operative X-ray.



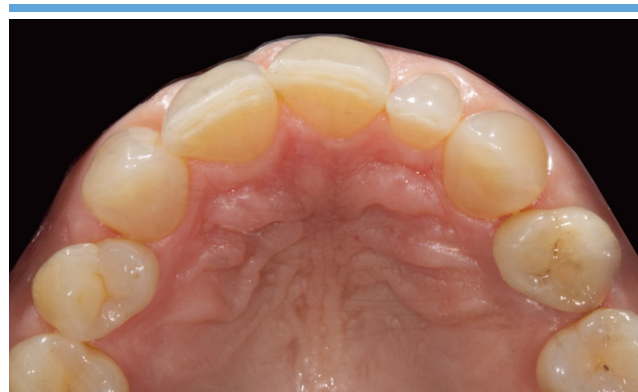12. Fitting of the temporary prosthesis – lateral view – D+0.



13. Removal of the sutures and check-up at D+10.



14a and 14b. Final restoration after 3 months. Lateral and occlusal view.



Conclusion

The current case involving immediate implant-based restoration was achieved using numerous digital tools such as 3Shape and ImplantStudio. Today, these tools allow us to plan our surgery in a safe and reproducible manner in just a few clicks, ensuring a digital workflow.

The optical impression combined with the CBCT images, the 3D impression and machining at the clinic, allows the surgical guide and the provisional prosthesis to be designed upstream at the operating

room. This gives us the option of preserving the anatomic architecture of the post-extraction site, and of guaranteeing the temporary provisionalisation during the osseointegration phase. This digitalisation of tasks following a process prevents any imprecision that is inherent in conventional techniques, as well as reduces surgery duration. For the patient, this type of planning reduces the number of visits required, which is an additional benefit to their quality of life.

References

[1] Linkevicius T, Apse P, Grybauskas S, Puisys, A. The influence of soft tissue thickness on crestal bone changes around implants: a 1-year prospective controlled clinical trial. *Int J Oral Maxillofac Implants* 2009;24: 712-719.

[2] Simensen AN, Bøe OE, Berg E, Leknes KN. Patient knowledge and expectations prior to receiving implant-supported restorations. *Int J Oral Maxillofac Implants* 2015;30:41-47.

[3] Yao J, Li M, Tang H, Wang PL, Zhao YX, McGrath C, Mattheos N. What do patients expect from treatment with dental implants? perceptions, expectatons, and misconceptions: a multicenter study. *Clin Oral Impl Res.* 2017;28(3):261-71.

[4] Zhang Y, Tian J, Wei D, Di P, Lin Y. Quantitative clinical adjustment analysis of posterior single implant crown in a chairside digital workflow: a randomized controlled trial. *Clin Oral Impl Res.* 2019;30(11):1059-66.

Dr. Thibaud Casas

Dental surgery and oral implantology practice
4 Bis Avenue Félix Vincent,
44700 Orvault
Telephone + 33 2 40 76 53 19
<https://www.docteur-casas.com>

- Dental surgeon and graduate of the Faculty of Dentistry at the University of Nantes
- Holder of a university undergraduate certificate and a university degree in oral implantology
- Trained in bone grafts and complex restoration work involving dental prosthesis, smile esthetics and digital dentistry techniques
- Member of the team on the maxillofacial surgery ward at Nantes University Hospital (CHU de Nantes).
- Trainer and speaker specializing in the use of digital technology in dental surgery and with dental prosthesis

Headquarters

CAMLOG Biotechnologies GmbH | Margarethenstr. 38 | 4053 Basel | Switzerland
Telephone +41 61 565 41 00 | Fax +41 61 565 41 01 | info@camlog.com | www.biohorizonscamlog.com

CAMLOG® is a registered trademark of Camlog Biotechnologies GmbH. It may however not be registered in all markets.
Bio-Oss® is a registered trademark of Geistlich Pharma AG
PIEZOSURGERY® is a registered trademark of mectron s.p.a.
Panavia™ is a trademark of Kuraray Noritake Dental Inc.
Manufacturer of CAMLOG® products: ALTATEC GmbH | Maybachstr. 5 | 71299 Wimsheim | Germany

